

CASE REPORT

Ring chromosome 8 [46 XY, r(8)]: array of manifestations in a 4 months old male child – a case report

Ankur Jindal¹, Komal Uppal¹ , Sunil Kumar Polipalli^{1*}, Seema Kapoor¹

ABSTRACT

Background: Ring chromosome 8 is a rare cytogenetic condition, with limited clinical and genetic characterization.

Case Presentation: We hereby report a case of a 4-month-old male child with craniofacial dysmorphism (microcephaly, aural dysplasia, anteverted nares, micrognathia, and visuo-ocular manifestations), global developmental delay, hypotonia, cryptorchidism, and other skeletal abnormalities. Investigations further facilitated the detection of semilobar holoprosencephaly, non-obstructive hypertrophic cardiomyopathy, and mal-ascended ectopic kidney.

Result: GTG-Banding revealed a Karyotype 46 XY, r(8) in the proband, while a normal parental karyotype suggesting non-inheritance of ring chromosome.

Conclusion: A wide array of features accompany ring chromosome 8 which have not yet been delineated into a recognizable syndrome.

Keywords: Case report, ring chromosome 8.

Introduction

Ring chromosomes are circular chromosomes that arise due to breakage and subsequent fusion of ends of linear chromosomes. An alternate mechanism of ring formation in chromosomes is attributed to telomeric dysfunction which leads to the conversion of non-sticky ends to sticky ends. Ring chromosomes can either be supernumerary or non-supernumerary. Supernumerary ring chromosomes (SRCs) constitute about 10% of small supernumerary marker chromosomes. These small SRCs are usually derived from regions adjacent to the centromere. Human non-supernumerary constitutional ring chromosomes are rare chromosome structural abnormalities (1:50,000 newborns) and can be found for all human chromosomes. Constitutional ring chromosomes are generally believed to be the result of de novo breakage of both end segments of a chromosome during meiosis or early postzygotic mitosis. Due to their circular structure, ring chromosomes may have problems in mitosis, which depends on sister chromatid exchange. Non-supernumerary rings replace the normal homologs and are represented as 46(r) karyotype. Ring chromosomes might be present only in a few cells (mosaic) or in all the cells. Variability in the

ring size and mitotic instability of the ring significantly contribute to diverse genotype-phenotype profiles in such cases. Some of the commonly described cases include ring chromosomes 4, 6, 18, and 20. The case described here is an example of non-supernumerary ring chromosome 8. Around 20 cases of ring chromosome 8 [r(8)] have been reported till now. The first case of ring chromosome 8 was described in 1973 by Pfeiffer and Lenard (1). We report a case of 4 ½ months old male Indian child with gross cranio-facial dysmorphism, hypotonia, holoprosencephaly, cardiac and renal malformations, and visuo-ocular abnormalities, whose karyotype was found to be 46 XY, r(8).

Correspondence to: Sunil Kumar Polipalli

*Division of Genetics and Metabolism, Department of Pediatrics, Maulana Azad Medical College (Delhi University), Delhi, India

Email: sunilpkumar18@gmail.com

Full list of author information is available at the end of the article.

Received: 08 June 2024 | **Accepted:** 09 September 2024



Case Presentation

The propositus was born on 30 December, 2016 (40 weeks POG) to a 28-year-old primigravida mother by lower segment cesarean section in view of fetal distress.

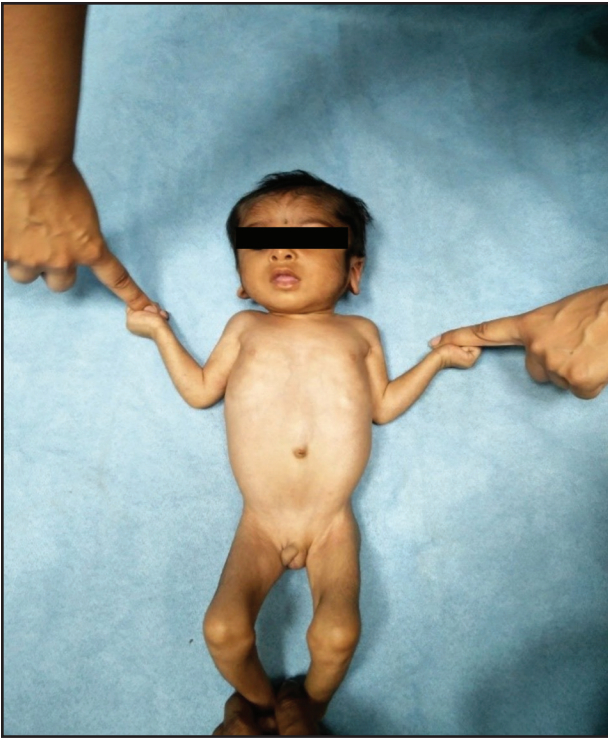

Figure 1. The patient at the age of 4 months; microcephaly, short stature, cranio-facial dysmorphism, and overriding fingers can be noted.

The antenatal period was largely uneventful. Routine prenatal scans during the 27th and 39th week indicated mild and moderate oligohydramnios, respectively, and suspected ventriculomegaly. The birth weight was 1,734 g (less than 3 S.D.; Low birth weight), length 46.8 cm (-1 to -2 S.D.), head circumference 30.6 cm (-2 to -3 S.D.), and an anterior fontanelle of 0.5 × 0.5 cm. The child had hypotonia at birth and developed respiratory distress within 6 hours of life, necessitating the initiation of supplemental oxygen. The child was referred to the genetic clinic at the age of 3 months in lieu of a wide array of gross congenital anomalies. On examination, there was microcephaly, hypotonia, frontal bossing, low anterior and posterior hair line, bilaterally epicanthal folds, medially downward slanting eyes, hypertelorism, micrognathia, narrow palate (leading to formula feeding), low set dysplastic ears, the flat nasal bridge with anteverted nares, long slender overriding fingers and toes, and cryptorchidism. Ocular examination revealed bilateral microphthalmia with microcornea which was more pronounced in the right eye. Frontal coloboma was seen in the left eye (Figures 1 and 2). Developmental assessment at the age of 4 months describe a lack of neck holding, bidextrous reach, and social smile indicative of motor and socio-adaptive delay.

Further investigations were done to detect other systemic abnormalities. Non-contrast computerized tomography of the head showed gross dilatation of the temporal horn, body, and occipital horns of both lateral ventricles which appear to be fused in the midline posteriorly without visualization of inter-ventricular septum and bilateral fused thalami, suggestive of Semi lobar holoprosencephaly (Figure 3a). Echocardiography revealed hypertrophic non-

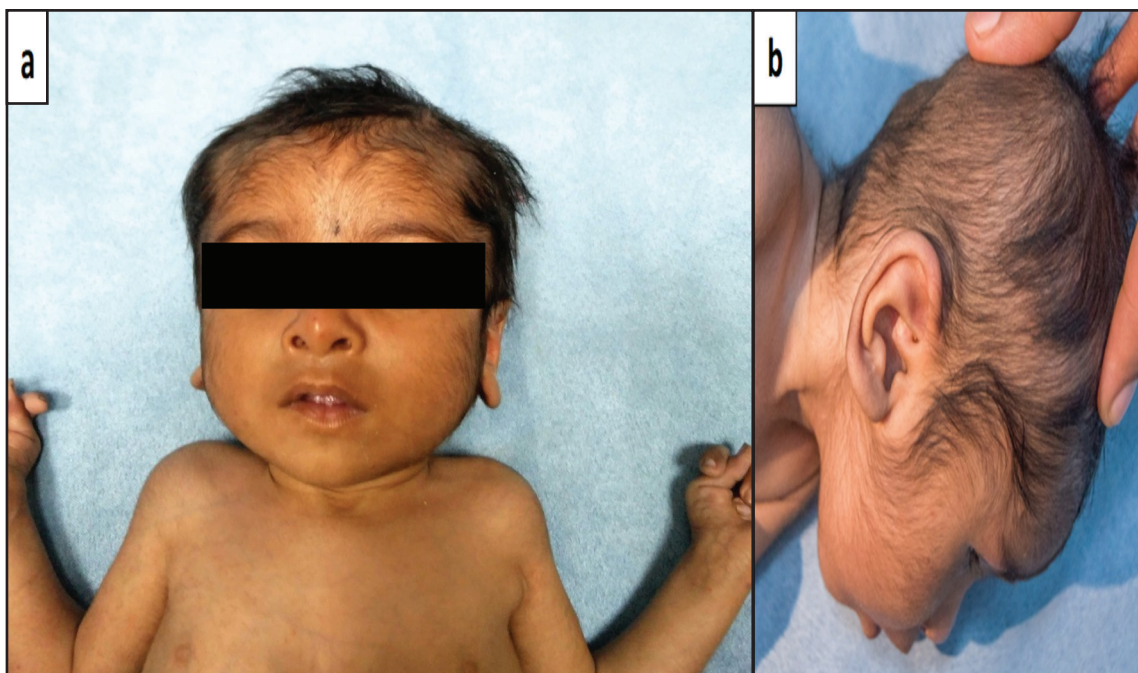

Figure 2. Facial profile (a. frontal and b. side); mongoloid slant, epicanthal folds, hypertelorism, anteverted nares, micrognathia (a), low anterior and posterior hair line and low set dysplastic ears (b) can be noted.

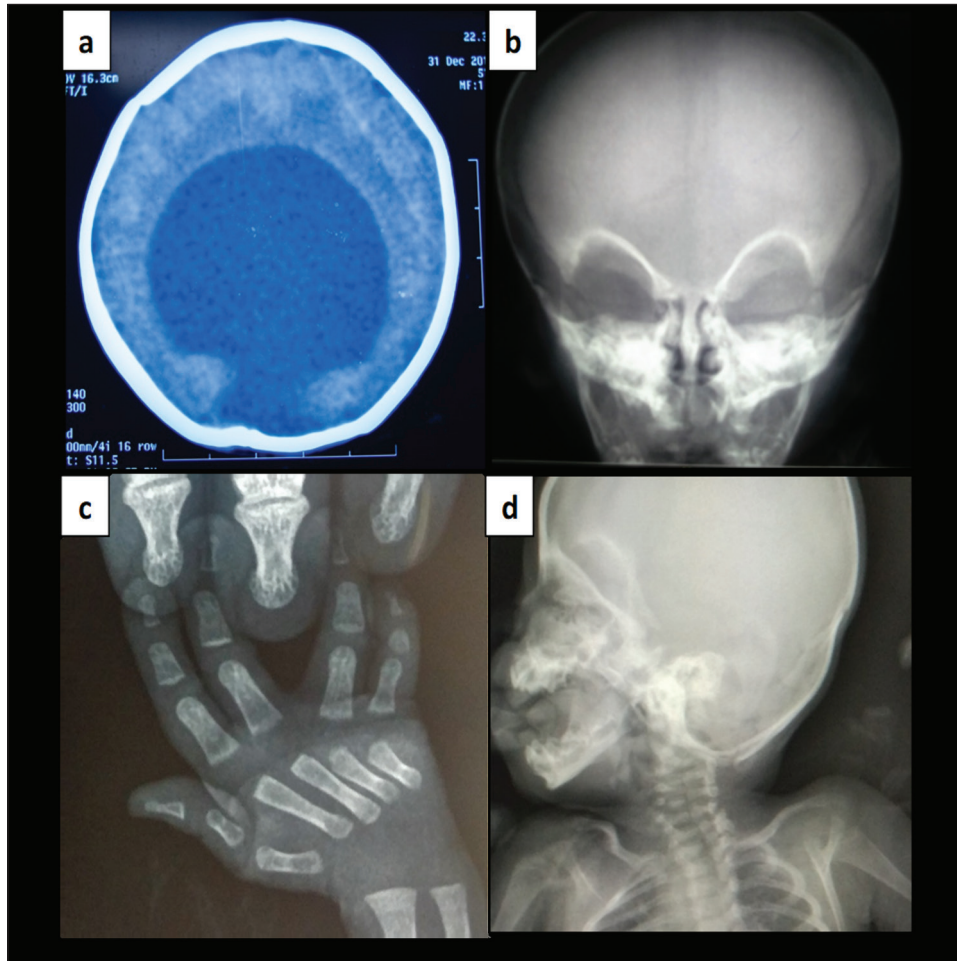


Figure 3. (a). NCCT head showing lateral ventricles fused in the midline, suggestive of holoprosencephaly. (b). X-ray skull showing decrease in AP (diameter s/o microcephaly, slant palpebral fissure and micrognathia). (c). Clinodactyly of fifth finger and angulation of metacarpals. (d). Cervical hemivertebrae.

obstructive cardiomyopathy. On ultrasound abdomen, the right kidney was mal-ascended and mal-rotated, present in the right iliac fossa. Radiological infantogram led to the identification of a decrease in Anteroposterior (AP) diameter (s/o microcephaly, slant palpebral fissure, and micrognathia), hemivertebrae and clinodactyly of the fifth fingers (Figure 3b–d).

Serum antibody assay was done both in mother and child to rule out vertical transmission of Toxoplasma, Rubella, Cytomegalovirus, Herpes (TORCH) infections. In the mother, immunoglobulin G titers were positive for Rubella and Cytomegalovirus while the TORCH profile in the child was insignificant.

Suspecting underlying chromosomal anomaly, karyotyping was done in the child as well as the parents. Standard cytogenetics performed on peripheral blood lymphocytes using Giemsa Banding (G-Banding) exhibited a karyotype of 46 XY, r(8) in all cells of the proband (Figure 4). Parental karyotype was normal indicating the child is a de novo case of ring chromosome 8.

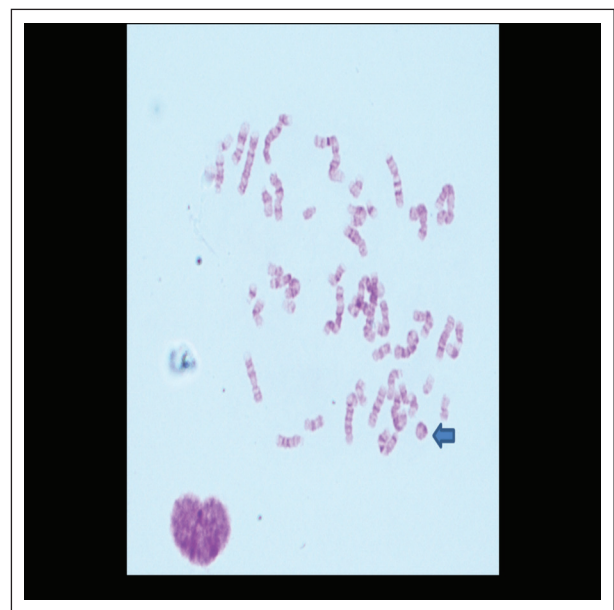


Figure 4. Giemsa banding of the patient showing ring chromosome 8 (marked by arrowhead).

Table 1. Clinical profile of the previously described cases of ring chromosome 8 broadly overlaps with this case.

	Pfeiffer et al. (1)	Mingarelli et al. (6)	Le Caignec et al. (7)	Gradek et al. (8)	Filges et al. (4)	Reported case
Karyotype	46 XY, r(8)	46 XX, r(8)	46 XY, r(8)/45 XY,-8	46 XY, r(8)/46 XY	47 XX, r(8)/46 XX	46 XY, r(8)
Microcephaly	+	+	+	Brachycephaly	-	+
Short stature	+	+	+	-	-	+
Facial dysmorphism	Turricephaly, flat occiput, micrognathia	Sloping forehead, flat face, flat nasal bridge	Small nose, anteverted nares, long philtrum, thin upper lip	Prominent ears	Prominent forehead, broad flat nasal bridge, short nose, long philtrum, thin upper lip, retrognathia, prominent ears	Frontal bossing, low anterior and posterior hairline, flat nasal bridge Anteverted Nares, low set dysplastic ears, micrognathia
Ocular findings	Hypotelorism	Mongoloid slant, hypertelorism, bilateral epicanthal folds	Bilateral amblyopia	Antimongoloid slant, bilateral epicanthus	Bilateral microphthalmia, eccentric nasal ectopia of pupils, severe astigmatism, posterior embryotoxon	Microphthalmia, bilateral epicanthal folds, hypertelorism, mongoloid slant; left frontal coloboma
Hypotonia				+	+	+
Skeletal abnormalities	Coxa valga	Brachydactyly of fifth fingers	Clinobrachydactily of fifth fingers	Brachydactyly of fifth finger	-	Long slender fingers and toes with clinodactyly of fifth fingers, hemimer-tebrae
Delay in development	N/A	N/A	N/A	Global delay	Global delay	Global delay
Mental retardation	Mild	Mild	mild	mild	-	N/A
Behavioral problems	N/A	Hyperactivity, kind personality	ADHD	ADHD, kind personality	-	N/A
Brain findings	-	-	-	-	-	Semilobar holoprosencephaly
Cardiac defects	-	-	-	-	Small muscular VSD	Non obstructive hypertrophic cardiomyopathy
Renal anomalies	-	-	-	-	Left pelvic kidney	Right ectopic mal-ascended kidney
Additional features	Cryptorchidism	-	-	Unilateral SNHL, broad neck, wide spaced nipples	Ventral placement of anus, Hirschsprung disease, hepatomegaly	Cryptorchidism, narrow palate

ADHD, Attention deficit hyperactivity disorder; VSD, Ventricular septal defect; N/A, Not Applicable; SNHL, Sensorineural hearing loss.

Discussion

Chromosomes are highly dynamic structures with regulated replication leading to the formation of two linear complementary strands that form a single duplex deoxyribonucleic Acid. However, any variation in the topology resulting in the formation of a ring can lead to a high degree of mitotic instability in the chromosome. Phenotypic manifestations of the ring chromosome are widely influenced by the chromosome which is aberrant and the microdeletions in the genome segment. Rarely, complete rings without any significant loss of genetic material have been described in individuals with apparently normal phenotypes (2).

Cases of ring chromosome 8 have been sparsely reported, of which the first reported case was by Pfeiffer and Lenard [46 XY, r(8)] in 1973 (1). The clinical profile of the previously described cases of ring chromosome 8 broadly overlaps with this case (Table 1). Melnyk et al. (3) reported the first case of SRC 8 [47 XX, +r(8)]. The reported cases of SRC 8 describe phenotypic anomalies like microcephaly, short stature, epicanthal folds, and clinodactyly which are largely consistent with those of non-supernumerary ring chromosome 8, including the present case (4). Holoprosencephaly and hemivertebrae are the novel findings present in this case. Ring chromosome 8 has also been described in association with certain myeloproliferative disorders (5) Table 1.

Frequently, ring chromosomes are formed due to microdeletions in the short and/or long arm of the chromosome, and hence the manifestations are determined by the genome segment which is deleted. Certain manifestations of the present case correspond to a suggestive deletion of 8q24.3 segment present on the telomeric region, predisposing to chromosomal instability and subsequent ring formation. Deletion of 8q24.3 has been attributed to the development of features like developmental delay, microcephaly, holoprosencephaly, clinodactyly, hemivertebrae, coloboma, and short nasal bridge which are consistent with this case (9,10). Major genes on Chromosome 8 are *FGFR1*, *EXT1*, *MTUS1*, *TRPS1*, *TNKS*, *GATA4*, *KAL1*, *KAL2*, *CHD7*, and *MYC* which are responsible for growth and development abnormalities, facial dysmorphism, neurological and cognitive dysfunction, skeletal abnormalities, and cancers.

Conclusion

In conclusion, conventional karyotype is a good diagnostic tool to diagnose chromosomal structural abnormalities. In the present case getting a definitive diagnosis emphasizes the knowledge of etiological diagnosis which can help in focusing on specific therapy, predicting recurrence risk, and the right counseling. Multiplex ligation-dependent probe amplification and chromosomal microarray can act as first-tier investigations to provide further diagnostic evidence of the micro deletions to expand their genotype-phenotype correlations better.

Acknowledgments

Gratitude to the Division of Genetics MAMC and the patient and his family.

List of Abbreviations

AP Anteroposterior
TORCH Toxoplasma, Rubella, Cytomegalovirus, Herpes

Declaration of conflicting interests

The authors of this article have no affiliations with or involvement in any organization or entity with any financial interest or non-financial interest in the subject matter or materials discussed in this manuscript.

Consent for publication

Informed consent was obtained from the parents of the patient.

Ethical approval

Ethical approval is not required at our institution to publish an anonymous case report.

Funding

None.

Author details

Ankur Jindal¹, Komal Uppal¹, Sunil Kumar Polipalli¹, Seema Kapoor¹

1. Division of Genetics and Metabolism, Department of Pediatrics, Maulana Azad Medical College (Delhi University), Delhi, India

References

1. Pfeiffer RA, Lenard HG. Ringchromosom 8(46, XY, 8 r) bei einem debilen Jungen. *Klin Padiatr.* 1973;185(3):187–91.
2. Guilherme RS, Meloni VF, Kim CA, Pellegrino R, Takeno SS, Spinner NB, et al. Mechanisms of ring chromosome formation, ring instability and clinical consequences. *BMC Med Genet.* 2011;12(1):171. <https://doi.org/10.1186/1471-2350-12-171>
3. Melnyk AR, Dewald G. Identification of a small supernumerary ring chromosome 8 by fluorescent *in situ* hybridization in a child with developmental delay and minor anomalies. *Am J Med Genet.* 1994;50(1):12–4. <https://doi.org/10.1002/ajmg.1320500103>
4. Filges I, Röthlisberger B, Wenzel F, Heinimann K, Huber AR, Miny P. Mosaic ring chromosome 8: clinical and array-CGH findings in partial trisomy 8. *Am J Med Genet A.* 2008;146A(21):2837–41. <https://doi.org/10.1002/ajmg.a.32520>
5. Kar B, Nandhini B, Revathi R. Ring chromosome 8 and trisomy 8 in a patient with acute myeloid leukemia. *Indian J Hematol Blood Transfus.* 2009;25(1):30–2. <https://doi.org/10.1007/s12288-009-0007-5>
6. Mingarelli R, Valorani G, Zelante L, Dallapiccola B. Ring chromosome 8 associated with microcephaly. *Ann Genet.* 1991;34(2):90–2.
7. Le Caignec C, Boceno M, Jacquemont S, Nguyen The Tich S, Rival JM, David A. Inherited ring chromosome 8 without loss of subtelomeric sequences. *Ann Genet.* 2004;47(3):289–96. <https://doi.org/10.1016/j.anngen.2003.10.005>
8. Gradek GA, Kvistad PH, Houge G. Monosomy 8 rescue gave cells with a normal karyotype in a mildly affected man with

- 46,XY,r(8) mosaicism. *Eur J Med Genet.* 2006;49(4):292–7. <https://doi.org/10.1016/j.ejmg.2005.08.004>
9. Verheij JB, de Munnik SA, Dijkhuizen T, de Leeuw N, Olde Weghuis D, van den Hoek GJ, et al. An 8.35 Mb overlapping interstitial deletion of 8q24 in two patients with coloboma, congenital heart defect, limb abnormalities, psychomotor retardation and convulsions. *Eur J Med Genet.* 2009;52(5):353–7. <https://doi.org/10.1016/j.ejmg.2009.05.006>
10. Dauber A, Golzio C, Guenot C, Jodelka FM, Kibaek M, Kjaergaard S, et al. SCRIB and PUF60 are primary drivers of the multisystemic phenotypes of the 8q24.3 copy-number variant. *Am J Hum Genet.* 2013;93(5):798–811. <https://doi.org/10.1016/j.ajhg.2013.09.010>