

CASE REPORT

Expanding the genetic spectrum of DNASE2 variants in the Middle East: first case of neonatal-onset autoinflammatory pancytopenia syndrome from Oman

Samiya Al Hashmi^{1*}, Aysha Tahera¹, Khalid Al Ryami¹, Abdullah Shahtta¹, Basim Abd El-Hady¹, Muna Al Alawi¹, Ali Al Jabri¹, Mujtaba Al AJmi¹, Requia Aljashmi², Aalya Al Maghari³, Aisha Al Balushi⁴

ABSTRACT

Background: The autoinflammatory pancytopenia syndrome (AIPCS) is a rare autosomal recessive disease caused by a mutation in the *DNASE2* gene that is characterized by severe anemia, thrombocytopenia, hepatosplenomegaly, and recurrent fevers.

Case Presentation: A case of a preterm female neonate born at 30 + 1 weeks by emergency cesarean section of consanguineous parents was presented, with subsequent antenatal findings of intrauterine growth restriction, fetal anemia, and hypertrophic cardiomyopathy. Postnatal evolution was conducted during admission to neonatal intensive care, with features of apnea, respiratory distress syndrome, persistent pancytopenia, and progressive hepatosplenomegaly. Laboratory and radiology findings indicated that a metabolic and genetic cause was likely, with suspicion raised of an interferon-mediated inflammation disorder. A genetic evaluation by whole exome sequencing showed a compound heterozygous *DNASE2* variant of uncertain significance (141_142del (p.Gly48AlafsTer49) and c.2T>C (p.Met1)). Ruxolitinib, a JAK inhibitor, was initially offered and later deferred due to prematurity and low birthweight, which started at the age of 5 months.

Conclusion: A rare genetic disease causing early-onset systemic autoinflammatory disease due to *DNASE2* mutation was identified. This study emphasized the importance of early detection and the establishment of genetic diagnostic methods for severe, multisystem, idiopathic neonatal inflammatory syndromes to prevent the progression of disease.

Keywords: Autoinflammatory, pancytopenia, preterm neonate, *DNASE2* gene, case report.

Introduction

The rare neonatal autoinflammatory disease is a challenge to diagnose, mainly in the neonatal period, as manifested with a variety of clinical features that can probably mimic congenital infections and could be rare genetic and metabolic causes. Neonatal autoinflammatory diseases encompass a diverse group of genetic disorders that are characterized by dysregulation in the innate immune system, typically manifesting as multisystem inflammation at an early age. Although it often occurs during the perinatal period, with presentation of systemic inflammation, cytopenia, and organ dysfunction.

Among this group of diseases, autoinflammatory pancytopenia syndrome (AIPCS) has been recognized as a unique condition characterized by autosomal recessive inheritance caused by biallelic mutations in the *DNASE2* gene found on chromosome 19p13.13 (1-3). It is

Correspondence to: Samiya Al Hashmi

*Department of Child Health, Royal Hospital, Muscat, Sultanate of Oman.

Email: samiyalhashmi@gmail.com.

Full list of author information is available at the end of the article.

Received: 19 December 2025 | **Accepted:** 24 January 2026



characterized by a combination of immune dysregulation, metabolic abnormalities, and systemic inflammation, manifested as severe anemia and thrombocytopenia apparent from early infancy, hepatosplenomegaly, and recurrent fevers associated with a hyperinflammatory state (1, 2, 4).

It can also be characterized by systemic features such as chronic diarrhea, renal manifestation with proteinuria, liver fibrosis with elevated liver enzymes, deforming arthropathy, and vasculitic skin lesions (1-4). A variety of symptoms might occur, with some patients exhibiting motor delay and learning difficulties as consequences of subcortical white matter lesions on brain imaging (2).

It leads to a hyperinflammatory state due to defective DNA degradation in macrophages, resulting in immune dysregulation and multisystem involvement (2). The DNASE2 gene encodes lysosomal deoxyribonuclease II, an acid endonuclease responsible for a crucial role in degrading DNA derived from apoptotic cells and erythroid precursors (1, 2, 5). It maintains the function of immune tolerance and prevents aberrant activation of the innate immune system. Any mutation in the DNASE2 gene can lead to the accumulation of undegraded DNA, triggering chronic type I interferon responses and contributing to autoinflammatory conditions such as interferonopathies (1, 5).

To date, only four cases have been reported in recent studies; all cases presented neonatal anemia (1, 2, 6). Recently conducted studies shed light on the mutation of DNase2-associated disease phenotypes, which have a variety of presentations in each individual (1-3). AIPCS was first described in infants with homozygous DNASE2 mutations presenting with persistent cytopenias, hepatosplenomegaly, and elevated inflammatory markers, often mimicking severe infectious or metabolic conditions (2).

While still under-recognized, several reports suggested that biallelic pathogenic variants in *DNASE2* lead to an interferonopathy with overlapping features of hemophagocytic lymphohistiocytosis (HLH) and congenital anemia signs that can be mistaken for other diagnoses, including HLH and primary bone (6).

In clinical situations, the AIPCS is overlooked, mainly in neonates, as it mimics with other hematological and congenital infection. Therefore, there is a need to increase the awareness of clinicians regarding the early onset and severity, as it can be presented with pancytopenia, recurrent fevers, hepatosplenomegaly, and cardiac involvement, in addition to marrow failure syndromes, sepsis, TORCH infections, or other congenital syndromes (2, 6). Nevertheless, understanding the symptoms of an autoinflammatory condition is essential for early and effective intervention.

Genetic approaches imply a significant role in the diagnosis of autoinflammatory syndrome (7). Recent research highlighted the impact of therapeutic advances of Janus kinase (JAK) inhibitors such as ruxolitinib and baricitinib in controlling inflammation caused by interferonopathy (1, 2, 6). Hong et al. (1) reported that patients with AIPCS showed clinical improvement

following targeted immunomodulation, highlighting the translational potential of precision therapies (1).

In the presented case, an AIPCS was identified in an Omani neonate, who presented new phenotypic-genotypic aspects to DNASE2-associated interferonopathies, which were previously undercharacterized in neonatal contexts. The report aimed to expand understanding of its neonatal phenotype and clinical awareness of DNASE2-associated interferonopathies. It highlighted the atypical presentation of prenatal and postnatal AIPCS features.

Case Presentation

A preterm neonate at 30 + 1 weeks was born to a primigravida mother and consanguineous parents by emergency caesarean section due to fetal bradycardia. An antenatal scan and assessment showed symmetrical intrauterine growth restriction (IUGR), severe fetal anemia, a single umbilical artery, and hypertrophic cardiomyopathy. This baby was born to consanguineous parents with a healthy primigravida mother, who had been admitted for a planned intrauterine blood transfusion. However, urgent delivery was required due to abnormal cardiotocography with sudden fetal distress and bradycardia. The infant was born with a low birth weight of 950 grams and APGAR scores of 8 and 9 at 1 and 5 minutes, respectively.

Soon after delivery, the neonate was admitted to the intensive neonatal care unit (NICU) for management of prematurity and IUGR. Despite initial stabilization, the neonate developed secondary apnea necessitating and requiring brief resuscitation with positive pressure ventilation. Respiratory support was initiated with continuous positive airway pressure, as the baby soon after birth developed tachypnea and respiratory distress. On day 7 of life, the baby developed respiratory acidosis, and escalation to invasive mechanical ventilation was promoted via endotracheal intubation. Ventilatory support was maintained for a total duration of 20 days, after which the patient was successfully extubated on day 33 of life. Subsequent weaning was achieved without supplemental oxygen, and the neonate was transitioned to room air by day 46 of life.

The routine laboratory investigation was conducted from birth and observed through the course of admission to NICU with persistent pancytopenia: hemoglobin 13.2 g/dL, platelets $16 \times 10^{12}/L$, white blood cells $1.3 \times 10^{12}/L$, and an absolute neutrophil count of zero. The neonate required multiple blood product transfusions with platelets, packed red blood cells, fresh frozen plasma, and cryoprecipitate. Biochemical and inflammatory markers showed that ferritin levels were significantly elevated (range: 3960-6924 $\mu\text{g}/L$), with low fibrinogen, high IL-2 receptor levels (>200 U/mL), and normal perforin levels. The initial differential diagnosis was figured out based on laboratory findings of neonatal hemophagocytic lymphohistiocytosis, metabolic liver disease, congenital bone marrow failure syndromes, or a congenital TORCH infection. Hence, the TORCH workup was carried out, which was negative, and the cytomegalovirus PCR was undetectable.

Later, during routine follow-up in the NICU, liver function tests were noted to be abnormal and worsening, showing high conjugated hyperbilirubinemia and elevated transaminases. A abdominal ultrasound revealed coarse hepatic echotexture and progressive splenomegaly (from 3.5 cm to 5.8 cm) (Figure 1A). Head ultrasound showed bilateral grade I intraventricular hemorrhage (IVH), which subsequently resolved, and a mild dilation of the ventricles (Figure 1B).

Gastroenterology was involved and advised initiating treatment with ursodeoxycholic acid and vitamin K supplementation due to persistent cholestasis with deranged liver enzymes. She was also diagnosed with metabolic bone disease and was managed hypercalcemia and hypophosphatemia. Moreover, she developed persistent systemic hypertension necessitating evaluation by pediatric nephrologist. The neonate was started on hydralazine therapy and had an echocardiographic diagnosis of a large patent ductus arteriosus, which was treated medically with one course of paracetamol.

During the neonatal intensive care unit (NICU) stay period, the infant developed feeding intolerance and was treated conservatively for suspected necrotizing enterocolitis. She responded to medical management and was maintained on a lactose-free formula. A septic workup was performed; blood cultures were initially negative but later grew MRSA and Acinetobacter complex from the endotracheal tube, prompting prolonged antibiotic therapy with meropenem and vancomycin for 21 days.

Despite aggressive supportive measures, the neonates' pancytopenia and liver abnormalities persisted, prompting genetic evaluation. Whole exome sequencing was sent and identified two heterozygous VUS in DNASE2: the first mutation with c.141_142del (p. Gly48AlafsTer49) revealed

a novel frameshift variant, and the second mutation with c.2T>C (p. Met1?) with a start-loss variant. These findings raised suspicion for compound heterozygous DNASE2-related AIPCS (Table 1).

Both variants were classified as VUS according to ACMG criteria, due to limited functional data and absence in population databases. However, given the compound heterozygous nature, consanguinity, phenotypic overlap with the AIPCS clinical phenotype, pancytopenia, hepatosplenomegaly, and elevated interferon markers, and lack of alternative diagnosis, a provisional diagnosis of DNase2-related AIPCS was considered.

A multidisciplinary team (MDT) consultation was conducted, including in pediatric hematology, metabolic genetics, pediatric rheumatology, pediatric gastroenterology, and the parent team of neonatology, with active parental involvement in shared decision-making with each team. Since the baby was in the neonatal intensive care unit (NICU), pediatric rheumatology agreed to start JAK inhibition. At 3 months of age, the patient was clinically stable on room air, with improving cytopenia and liver function, and was discharged home with regular follow-up with pediatric rheumatology and hematology. At 5 months of age, ruxolitinib, a JAK inhibitor, was formally initiated. The child remained clinically well during routine follow-up with normalization of inflammatory markers.

Discussion

In this report, we examined the manifestations of an autoinflammatory syndrome in a neonate with rare disease features and complex multisystem involvement, including prenatal diagnoses of anemia, hypertrophic cardiomyopathy, and intrauterine growth restriction, and

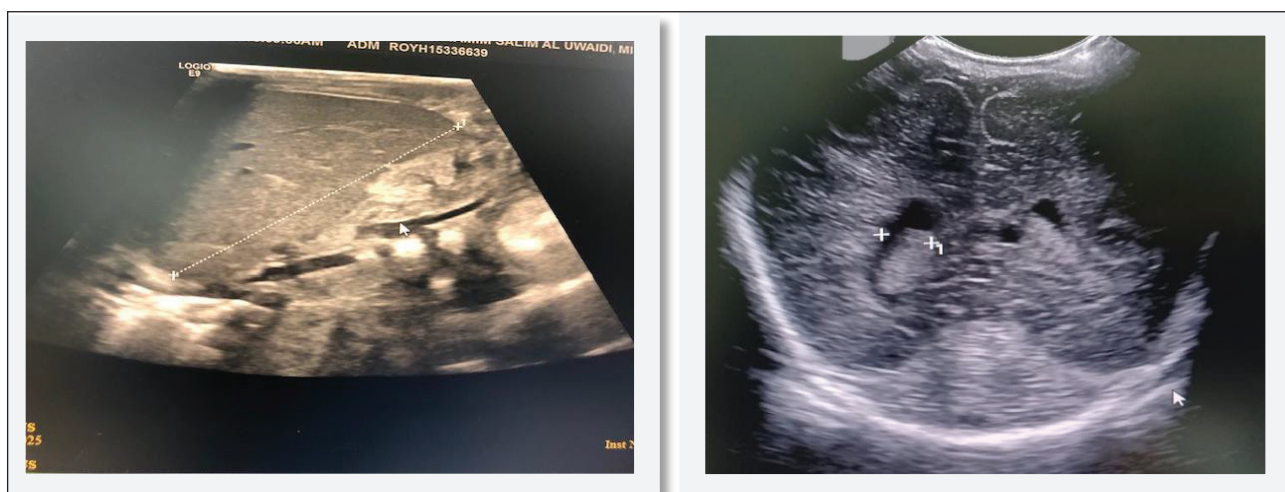


Figure 1. (A) Abdominal US revealing coarse hepatic echotexture and progressive splenomegaly. (B) Head US showing bilateral grade I IVH.

Table 1. Different mutations of the DNASE2 gene in the present case.

Gene	Variant (HGVS)	Protein impact	Classification
DNASE2	c.141_142del	p.(Gly48AlafsTer49)	Frameshift - Uncertain significance (Class 3)
DNASE2	c.2T>C	p.(Met1?)	Start-lost - Uncertain significance (Class 3)

Table 2. The variety of clinical features of the reported cases compared with the present case.

Feature	Rodero et al. (2)	Hong et al. (1)	Present case
In Utero (fetal anemia, cardio-myopathy , intrauterine growth restriction (IUGR))	No	No	Yes
Neonatal anemia/thrombocytopenia	Yes	Yes	Yes
Hepatosplenomegaly	Yes	Yes	Yes
Pancytopenia	Yes	Yes	Yes
Cholestatic hepatitis/liver fibrosis/ Deranged with liver enzymes	Yes	Yes	Yes
Neurologic abnormalities	Mild patchy, sub-cortical white matter lesions in the parietal lobes (brain MRI)	Bilateral deep white matter lesion (brain MRI), motor delay	IVH, mild dilation
Whole exome sequencing (WES)	Homozygous missense	Homozygous missense	Compound heterozygous VUS in DNASE2 mutation (c.141_142del (p.Gly48AlafsTer49) - a novel frameshift variant, second mutation (c.2T>C (p.Met1?) - a start-loss variant

postnatal findings of persistent pancytopenia, abnormal liver enzymes, and progressive hepatosplenomegaly.

These clinical findings were unusual for a general neonatal illness and suggested a systemic inflammatory disease involving hematological and hepatic disorders. It was a key observation in the determination of the atypical presentations of a serious, neonatal-onset phenotype of AIPCS, as shown by the spread of its clinical presentation that had started in utero and persisted through to postnatal.

The recent research by Rodero et al. (2) described the first three cases with two siblings and another from a different family and was later followed by Hong et al. (1), who described one case in their report with similar manifestations (1, 2). Both studies showed that affected children had homozygous missense mutations in DNASE2, characterized by pancytopenia, hepatosplenomegaly, neurologic abnormalities, and elevated interferon signatures. Notably, these cases were diagnosed during infancy or early childhood, with no documented prenatal manifestations (1-3).

Another notable finding in the present case was the presence of the presence of manifestation of metabolic bone disease, feeding intolerance, and systemic hypertension not commonly associated with DNASE2 mutations, which could further broaden the clinical spectrum of associated DNASE2 (8), which suggested a more severe or penetrant phenotype in compound heterozygous states that has not been previously documented in neonatal cases (Table 2).

By contrast to the earliest studies of Rodero et al. (2) and Hong et al. (1), (1, 2), the presented case had a unique presentation of genetically carrying heterozygous variants of uncertain significance, specifically, a novel frameshift mutation (c.141_142del; p.Gly48AlafsTer49) and a start-loss mutation (c.2T>C; p.Met1?). These variants have not been

previously described in the literature and might represent a more severe or penetrant genetic configuration.

The DNASE2 gene has a critical role in the functioning of lysosomal DNA degradation, particularly in the clearance of erythropoiesis and apoptotic cells. The defect induced by the DNASE2 gene is undigested DNA-dependent and accumulates in lysosomes, leaking into the cytosol, where it activates the cGAS-STING pathway, which results in chronic type I interferon production (1, 5).

This defect of the DNASE2 mechanism was well-characterized in murine models, where Ahn et al. (5) showed that DNASE2-deficient mice were lethal in the embryo due to the presentation of severe anemia and systemic inflammation induced by interferon signaling. These results confirmed the support that the pathophysiology of DNASE2 malfunction is interferon-mediated immune dysregulation, which is clinically manifested with cytopenia, hepatosplenomegaly, and systemic inflammation (1, 2, 5). High ferritin and IL-2 receptor levels, sustained pancytopenia, and liver dysfunction observed in the current case fall in line with the characteristics of interferonopathy disorders (2). Even though interferon signature profiling was not applied in this case, the clinical and genetic results highly indicated that the activation of the immune system through STING is being triggered by a mutation in the DNASE2 gene. It is essential to carry out early genetic assessment of children who have cytopenias of undetermined etiology as well as liver abnormalities and systemic inflammation in infancy (2, 7).

The JAK inhibition, in this case, was triggered with the ruxolitinib, leading to clinical improvement and normalization of inflammatory markers (1). Their application of JAK inhibition to DNASE2-associated AIPCS, by the positive response in the current case, indicated that timely intervention could help prevent the irreversible damage of the organ. Moreover, this case

showed the importance of collaboration, which was achieved when a team comprised of multiple specialists, who in this case were the parent team, neonatology, pediatric hematology, rheumatology, gastroenterology, and genetics. Teamwork enabled the management of complicated clinical progression and treatment plans. The researchers had shortcomings associated with the uncertainty in the classification of DNASE2 variants that were not reported in the literature, the absence of interferon signature testing, and the lack of bone marrow biopsy examination. Another limitation of this case report is the absence of parental testing, and therefore, compound heterozygosity could not be definitively established.

Conclusion

This report provided useful novel insights into the uncharacteristic expression of AIPCS, a neonatal-onset phenotype of type I interferonopathy with DNASE2 dysfunction, causing abnormal activation of the innate immune system. The report enhanced the clinical understanding of DNase2-related type I interferonopathies, which can help establish early diagnosis, enable effective therapeutic strategies, and offer family counselling.

List of Abbreviations

ACMG	American College of Medical Genetics and Genomics
AIPCS	Autoinflammatory pancytopenia syndrome
CTG	Cardiotocography
IUGR	Intrauterine growth restriction
IVH	Intraventricular hemorrhage
JAK	Janus Kinase
NEC	Necrotizing enterocolitis
NICU	Neonatal intensive care unit
PCR	Polymerase chain reaction
TORCH	Toxoplasmosis, other: syphilis, varicella, rubella, cytomegalovirus, herpes
VUS	Variant of uncertain significances

Funding

This research received no specific grant from any funding agency in the public, commercial, or not-for-profit sectors.

Conflict of interests

The authors of this article have no affiliations with or involvement in any organization or entity with any financial interest or non-financial interest in the subject matter or materials discussed in this manuscript.

Consent for publication

Due permission was obtained from the parents of the patient to publish the case and the accompanying images.

Author Contributions

All the authors listed in this article made a contribution in the acquisition of data from the patient's parents, drafting and

writing the manuscript, and final approval of this version to be published.

Ethical Approval

Ethical approval was granted by the Royal Hospital Research Committee, Ministry of Health, Oman, via reference number MOH/CSR/CR/25/16. Dated: 30-11-2025.

Author details

Samiya Al Hashmi¹, Aysha Tahera¹, Khalid Al Ryami¹, Abdullah Shahtta¹, Basim Abd El-Hady¹, Muna Al Alawi¹, Ali Al Jabri¹, Mujtaba Al Ajmi¹, Requia Aljashmi², Aalya Al Maghari³, Aisha Al Balushi⁴

1. Department of Child Health, Neonatal Intensive Care Unit, Royal Hospital, Muscat, Oman
2. Department of Child Health, Pediatric Rheumatology Unit, Royal Hospital, Muscat, Oman
3. Department of Child Health, Pediatric Haematology Unit, Royal Hospital, Muscat, Oman
4. Department of Child Health, Pediatric Metabolic & Genetic Unit, Royal Hospital, Muscat, Oman

References

1. Hong Y, Capitani M, Murphy C, Pandey S, Cavounidis A, Takeshita H, et al. Janus kinase inhibition for autoinflammation in patients with DNASE2 deficiency. *J Allergy Clin Immunol.* 2020;145(3):701–5.
2. Rodero MP, Tesser A, Bartok E, Rice GI, Della Mina E, Depp M, et al. Type I interferon-mediated autoinflammation due to DNase II deficiency. *Nat Commun.* 2017;8:2176.
3. OMIM Entry 619858. Autoinflammatory-pancytopenia syndrome. Available from: <https://www.omim.org/entry/619858>
4. National Center for Biotechnology Information (NCBI). Autoinflammatory-pancytopenia syndrome due to DNASE2 deficiency (AIPCS). Bethesda (MD): U.S. National Library of Medicine. Available from: <https://www.ncbi.nlm.nih.gov/medgen/1803642>
5. Ahn J, Gutman D, Saijo S, Barber GN. Accumulation of DNA in lysosomes triggers interferon responses via the STING pathway. *Cell.* 2012;152(3):748–62.
6. Schnappauf O, Rice GI, de Jesus AA, Kuehn HS, Lee JS, Kim H, et al. Janus kinase inhibition for autoinflammation in DNASE2 deficiency. *Res Square.* 2025. <https://doi.org/10.21203/rs.3.rs-7039031/v1>
7. Batlle-Masó L, Mensa-Vilaró A, Solís-Moruno M, Marqués-Bonet T, Arostegui JI, Casals F. Genetic diagnosis of autoinflammatory disease patients using clinical exome sequencing. *Eur J Med Genet.* 2020;63(5):103920. <https://doi.org/10.1016/j.ejmg.2020.103920>
8. Poker Y, Von Hardenberg S, Hofmann W, Tang M, Baumann U, Schwerk N, et al. Systematic genetic analysis of pediatric patients with autoinflammatory diseases. *Front Genet.* 2023;14:1065907. <https://doi.org/10.3389/fgene.2023.1065907>